

## Recalcitrant corneal ulcer

Anubha Rathi<sup>1</sup>, Namrata Sharma<sup>1</sup>, Neelima Aron<sup>1</sup>, Rajesh Sinha<sup>1</sup>, Tushar Agarwal<sup>1</sup>

A corneal ulcer is defined as loss of surface corneal epithelium along with infiltration into the surrounding and underlying layers. It may be infectious or non infectious. Non infectious causes of corneal ulcer include mechanical trauma, chronic irritation, contact lens induced or nutritional deficiency. The infectious causes include bacteria, fungi, viruses and protozoa. Recalcitrant corneal ulcer refers to a corneal ulcer which does not respond to the conventional treatment (Figure1). Response of a corneal ulcer to treatment is indicated by decrease in size of the epithelial defect or infiltrates. The time frame for resolution differs for various etiologies of a corneal ulcer. In case of a bacterial or viral corneal ulcer, a recalcitrant corneal ulcer is defined as an ulcer showing no signs of improvement in terms of reduction in size of epithelial defect or infiltrates even after 48 hours of initiation of the specific anti microbial treatment. In case of a fungal corneal ulcer, this time period is extended up to 5-6 days.

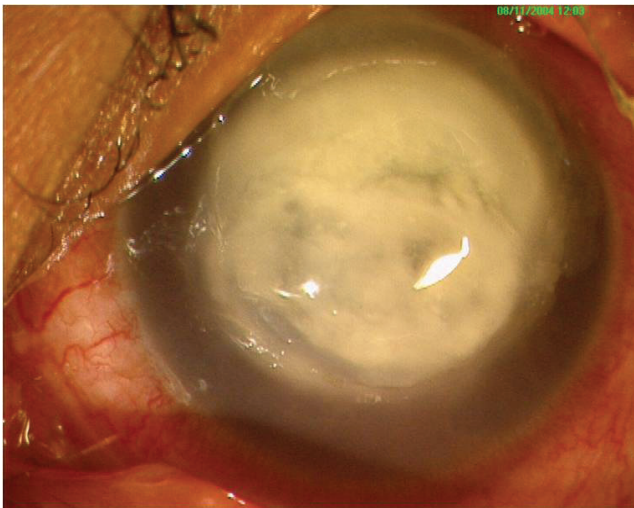


Figure 1: Non resolving corneal ulcer

### Epidemiology:

As per WHO, Corneal blindness is one of the leading causes of blindness worldwide<sup>1</sup>. This proportion is higher in tropical developing nations such as India. Most cases of corneal blindness are due to corneal ulcers or keratitis. Microbial keratitis is hence a leading cause of ocular morbidity<sup>2</sup>. Timely diagnosis and treatment may reduce the morbidity and extent of visual impairment in these conditions. But sometimes despite the best diagnostic techniques, some cases of microbial keratitis do not respond to the conventional treatment. Most of these cases are seen to be associated with drug resistant micro organisms which make the treatment even more difficult. Rampant use of over the counter topical antibiotics has a role to play in the development of multi drug resistant micro organisms which has further increased the incidence of recalcitrant microbial keratitis.

### Causes of recalcitrant keratitis:

A non resolving corneal ulcer is an ophthalmologist's nightmare. A systematic approach is hence required to rule out all the possible causes of a recalcitrant ulcer.

First and foremost, the nature of treatment already administered needs to be evaluated. Incomplete treatment is one of the leading causes of a corneal ulcer to be labeled as non resolving. Before labeling the ulcer as non resolving, an accurate diagnostic corneal scraping and culture sensitivity along with alteration of the treatment if required should have been done. Hence most of these cases are incorrect diagnoses in the setting of incomplete investigations or treatment.

Most of the fortified anti microbial therapy that is initiated in these cases is epitheliotoxic and may in few cases itself impede re epithelialisation of healthy corneal epithelium<sup>3</sup>.

<sup>1</sup>Dr R P Center of Ophthalmic Sciences, All India Institute of Medical Sciences, New Delhi, India.

Corresponding Author : Prof. Namrata Sharma, E-mail: namrata.sharma@gmail.com

Received on : 08/10/2016, Revision accepted on : 18/11/2016

Conflict of Interest : None, Financial Disclosure : None

© Current Indian Eye Research.

Even in the best possible situation with accurate and timely corneal scraping and microbiological examination along with timely initiation of anti microbial treatment, some ulcers do not show any improvement. With increasing incidence of drug resistant micro organisms, such ulcers are on the rise. Microorganisms develop resistance to the anti microbial treatment by genetic mutation and inductive expression of latent chromosomal genes with exchange of genetic material via transformation, bacteriophage transduction or plasmid conjugation<sup>4</sup>.

In certain cases, the size and extent of the ulcer is already large reaching upto the limbus with impending perforation at the time of presentation to the ophthalmologist. In such cases, standard anti microbial treatment may not work. They may require surgical intervention. Atypical micro organisms may also cause corneal ulcers not responding to the routine treatment.

Adnexal abnormalities such as eye lid malposition may also affect the healing process of a corneal ulcer<sup>5</sup>. Co existing Thyroid eye disease with axial proptosis and lagophthalmos may impair the normal healing process of the ulcer despite suitable antimicrobial treatment<sup>6</sup>.

Patients with systemic diseases such as Diabetes mellitus are known to have delayed healing and may develop a recalcitrant corneal ulcer.

**Table 1. Causes of a recalcitrant corneal ulcer**

1. Incomplete treatment
2. Epitheliotoxic drugs
3. Inaccurate diagnosis/ scraping
4. Drug resistant micro organisms
5. Atypical micro organisms
6. Advanced severe corneal ulcers
7. Ulcers with impending perforation or already perforated
8. Posterior segment involvement with endophthalmitis or Intra ocular retained Foreign body
9. Immuno compromised state
10. Diabetes mellitus
11. Adnexal abnormalities such as lid malposition
12. Co existing thyroid eye disease

Other immune compromised conditions such as HIV-AIDS, patients on immune suppressive treatment, anti cancer drugs etc are also prone to develop recalcitrant corneal ulcers<sup>7</sup>.

Non infective recalcitrant corneal ulcers may be associated with mechanical trauma to the cornea in the form of papillae or follicles in upper lid palpebral conjunctiva as seen in trachoma.

The possible causes of a recalcitrant corneal ulcer are summarized in Table 1.

### Clinical Presentation:

A case of a non healing or recalcitrant ulcer usually presents with an acute red eye with complaints of redness, pain, photophobia and vision loss. There may be a history of trauma with vegetative material or a febrile viral illness. Such history may be a pointer towards the probable etiology of the ulcer and may guide the treatment.

#### A. History and Symptoms:

The presence of pain is due to the irritation to the sensory nerve fibres present in the superficial layers of the cornea. The nature of pain is also an indicator of the probable cause. Bacterial keratitis is usually characterized by significant pain. Fungal keratitis is usually not associated with severe pain. Acanthamoeba keratitis is characterized by severe pain owing to radial keratoneuritis. This pain is usually out of proportion to the size and extent of the ulcer. Herpetic dendritic ulcers are usually associated with minimal pain. In cases of recalcitrant corneal ulcers, a mixed picture may be present thereby complicating the diagnosis based on history. A sudden relief in pain in such cases may indicate a perforated corneal ulcer. Bacterial keratitis usually has a sudden onset with rapid progression whereas fungal and acanthamoeba keratitis typically have a chronic course.

#### B. Predisposing Factors:

For timely initiation of empirical anti microbial treatment before the microbiological evidence becomes available, it is important to look for the specific predisposing factors which would point towards a specific etiology. Corneal trauma by a vegetative matter usually leads to mycotic ulcer. Prolonged contact lens wear especially overnight or extended wear soft contact lenses may cause corneal ulcers especially due to infection by the Pseudomonas species<sup>8</sup>. Exposure to dirty swimming pool water or pond

water and contaminated contact lens solutions has been seen to be associated with Acanthamoeba keratitis. Atypical causes such as Pneumococcus are seen to be associated with co existing dacryocystitis.

In case of recalcitrant corneal ulcer, the medications that the patient has been prescribed earlier for the ulcer need evaluation. Topical corticosteroids may worsen a case of probable mycotic keratitis rapidly<sup>9</sup>. The use of non steroidal anti inflammatory agents has been associated with worsening of corneal ulcers and in rare cases may cause corneal melt as well<sup>10</sup>.

History of previous ocular surgery including cataract and refractive surgery is important. Post LASIK corneal ulcers may be due to atypical mycobacteria<sup>11</sup>.

### C. Ocular Examination:

#### ● Visual Acuity

A central or large corneal ulcer may significantly impair the visual acuity of the patient. In advanced severe ulcers with posterior segment involvement, there may be an inaccurate projection of rays (PR) as well.

#### ● Adnexa

It is important to rule out eyelid malpositions, lagophthalmos, proptosis, blepharitis, dacryocystitis which may impede the healing process of the corneal ulcer. Lid or lacrimal system abnormalities need to be addressed along with the ulcer.

#### ● Conjunctiva

Gonococcal, Pneumococcal and Haemophilus corneal ulcers are rare but are characterized by severe conjunctival injection. A greenish purulent discharge may indicate that Pseudomonas keratitis is the likely cause.

#### ● Cornea

In order to diagnose a case of recalcitrant keratitis, sequential corneal examinations need to be done for location, size and depth of the corneal ulcer. A schematic diagram should be drawn at each visit.

#### o Location:

The ulcer may be central, paracentral or peripheral. Isolated peripheral ulcers are seen with Herpes simplex virus and Mycobacterial tuberculosis. There may be multiple islands of ulcer. Each ulcer needs to be schematically drawn for the sake of future record to look for any response to treatment.

#### o Shape:

Dry looking ulcers with feathery margins and stellate lesions are usually mycotic. Dendritic ulcers are characteristic of Herpes simplex keratitis. Ring ulcer is indicative of Acanthamoeba keratitis. Bacterial ulcers are usually wet looking with punched out appearance.

#### o Margins of the ulcer:

In case of peripheral ulcerative keratitis, overhanging edges are characteristically present in case of Moorens ulcer.

#### o Size:

The most important indicator of response to treatment in case of a corneal ulcer is the size of both the epithelial defect and the surrounding infiltrates. Using the slit lamp biomicroscope with in-built micrometer, an accurate determination of the size of ulcer in all dimensions is possible.

An accurate measurement of the size of the corneal ulcer needs to be done and recorded.

The epithelial defect is measured after staining it with Fluorescein stain or Rose Bengal stain. Rose Bengal stain is specific particularly for viral herpetic dendritic keratitis.

The size, density and depth of infiltration should be recorded in detail and used as reference in follow up to evaluate response of the corneal ulcer to treatment.

#### o Corneal sensations :

Corneal sensations can be checked with the help of cotton wisp or with Cochet-Bonnet aesthesiometer. They are particularly decreased in case of viral keratitis.

#### ● Anterior Chamber

A hypopyon may be associated with any corneal ulcer. Mycotic keratitis is usually associated with a fixed hypopyon that does not change position despite making the patient lie supine for at least 10 minutes.

#### ● Posterior Segment

Posterior segment needs to be assessed for the presence of any retained intraocular foreign body or co existing endophthalmitis which may be the predisposing factors for recalcitrant keratitis.

#### Documentation:

Documentation of location, size, shape, vascularisation of a corneal ulcer is very important. It becomes even more

important in case of a recalcitrant corneal ulcer. It can be done either by colour clinical photographs or by schematic diagram.

#### ● *Clinical Photography (CP)*

CP of the index eye needs to be taken at regular intervals. Both diffuse and slit sections need to be recorded. Measurements should be done using in built micrometer.

#### ● *Schematic Diagram*

In many ways, the age old schematic corneal drawings are superior to clinical photography. A lot of details which may not get highlighted can be duly pointed out effectively using a well drawn corneal diagram. But the limitation is time, effort and skill. A schematic diagram carries significance only when it abides by the standard colour coding. This becomes even more important when more than ophthalmologist examines the patient.

Black colour is meant for limbus, scars, foreign bodies, deposits, guttae, sutures, tissue adhesive and lipid keratopathy. Blue colour denotes edema and bullae. Stromal edema is depicted by shading while epithelial edema is drawn using small circles. Wavy blue lines denote the Descemet's membrane folds. Brown colour is for pupil, iris and melanin or iron pigmentation. Red colour is used to depict vascularisation. Straight red lines indicate stromal vessels while wavy lines are for sub epithelial vessels. Dotted lines depict ghost vessels. Superficial vascularisation begins outside the corneal circle whereas deep vessels begin at the margin of the circle. Orange colour is used to indicate collection of white blood cells such as stromal infiltrates, Keratitic precipitates and hypopyon. Green colour denotes fluorescein staining of

the epithelial defect or dendrites. The colour coding of the cornea is summarized in Table 2.

#### **Investigations:**

Both ocular and systemic investigations hold importance in case of a recalcitrant keratitis. Systemic investigations to rule out conditions associated with delayed healing should be done at the earliest. This includes a battery of investigations including fasting and post prandial blood sugar, complete hemogram, urine analysis, renal function test and liver function test. In suspected cases, further immunological work up including HIV ELISA, ESR, ANA, ANCA, RF may be required.

Among the ocular investigations, measurement of IOP and ultrasonography are done to rule out secondary glaucoma and evaluate the posterior segment respectively. The primary ocular investigation that holds special diagnostic importance is Corneal Scraping. In a case of recalcitrant keratitis, the previous treatment needs to be withdrawn at least for 24-48 hours and fresh corneal scraping taken using standard techniques.

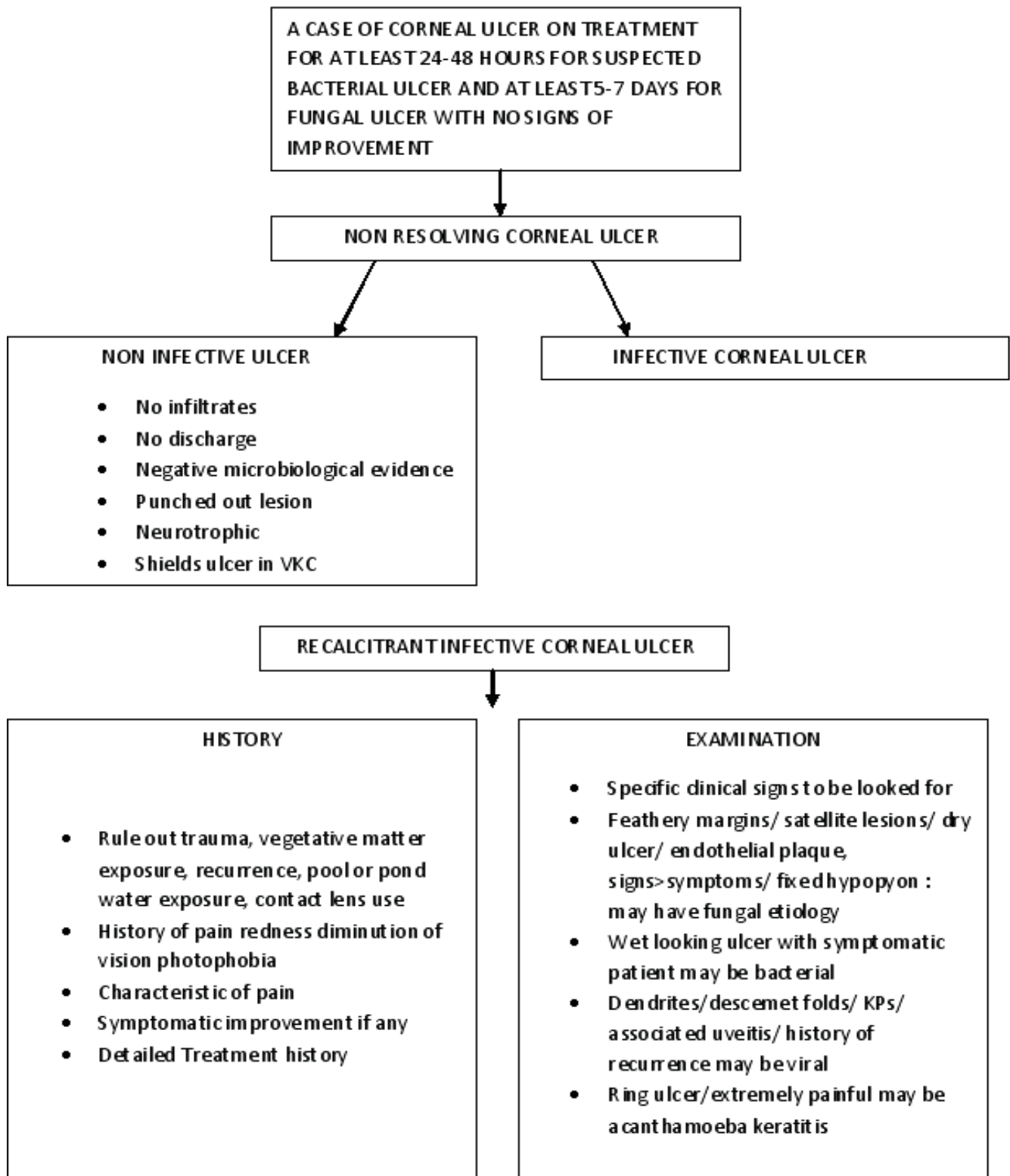
If there is any conjunctival discharge or lacrimal sac discharge or bandage contact lens, they should be separately sent for microbiological testing.

Corneal scraping is ideally done under topical anaesthesia using 0.5 percent paracaine drops. It is routinely done on a slit lamp biomicroscope. In case of small children and uncooperative patients, a general anaesthesia may be needed and scraping is then done under operating microscope. A corneal scraping sample is ideally obtained using Kimura's spatula. Other instruments that may be used for this purpose include Bard Parker blade number 57, surgical blade number 15 and 26 gauge needle. It is important to be cautious and not cause any perforation while scraping especially with a needle. Before corneal scraping, all the debris and drug deposits need to be swabbed away first. Then the sample is taken from the leading edges and base of the ulcer. It is important to brush the instrument in a single direction. In ideal circumstances with good and timely microbiology assistance at hand, the scraping sample should be plated onto the culture plate of choice straight away. This 'eye to the plate' technique increases the productivity of corneal scraping and decreases the chance of sample drying off or inadequate sample. Along with culture, other microbiological investigations that need to be done include Gram staining, Giemsa staining, Ziehl Nelson staining, KOH wet mount. Other stains and culture may be done in cases with strong

**Table 2. Schematic colour coding of cornea**

Color	
Black	Scar, degeneration, deposits, foreign body, tissue adhesive, limbus, lipid keratopathy
Blue	Edema, bullae, Descemet folds
Brown	Iris, iron or melanin pigmentation
Orange	Keratitic precipitates, hypopyon, stromal infiltrates
Green	Florescein stained epithelial defect, dendrites, vitreous
Red	Vascularisation, hemorrhage

**APPROACH TO CASE OF RECALCITRANT CORNEAL ULCER**



suspicion of atypical organisms.

It is important to have an adequate sample and accurate staining and fixing skills to be able to diagnose the causative micro organism and start anti microbial therapy accordingly. This step is the usual limiting factor in cases labeled as recalcitrant keratitis. Hence it is advisable to stop all treatment in such cases for 24-48 hours and repeat the scraping process accurately.

The routine smears and stains have their own limitations. Gram stain is able to identify the causative organism in 75 percent cases while 10 percent KOH wet mount has a sensitivity of 92% and specificity of 96%<sup>12-14</sup>.

Other stains that can be used in suspected cases include Calcofluor white for Acanthamoeba and Ziehl Nelson for mycobacteria and nocardia.

Corneal scraping is inoculated onto culture plate in order to culture the micro organism. These plates are temperature sensitive. Hence an accurate diagnosis requires good microbiological laboratory assistance and facilities. Commonly used culture media include Blood agar plate, Chocolate agar plate and Sabouraud's dextrose agar. Other culture media that can be used if a particular organism is suspected include Thioglycollate broth for anaerobes, Lowenstein Jensen medium for mycobacteria, Brain heart infusion for fungi and E.coli enriched non nutrient agar for Acanthamoeba.

A negative culture report may indicate partial antibiotic treatment, inadequate sample, inaccurate culture techniques etc. Such cases go on to become recalcitrant due to lack of directed anti microbial therapy<sup>15</sup>.

Once the organism has grown on the culture plate, an antibiotic sensitivity testing is done and accordingly the treatment may be altered or started in these cases.

Other investigations such as Confocal microscopy and serological testing including PCR may also aid in the diagnosis.

A corneal biopsy or a suture biopsy may be done in deeper ulcers where superficial corneal scraping fails to reveal any micro organism<sup>16</sup>. Corneal biopsy may be done using a crescent blade or Bard Parker blade. Suture biopsy is usually taken using a 10-0 monofilament nylon suture or a vicryl suture.

An anterior chamber paracentesis may be taken and sent for microbiological investigation in cases of hypopyon corneal ulcer<sup>17</sup>.

## Management of A Case of Recalcitrant Keratitis

A case of recalcitrant keratitis requires a systematic step wise approach. The initial steps of history taking and examination are same as any fresh case of corneal ulcer. Once the basic history taking and clinical examination is over, the first step is to stop all the treatment the patient is being given for at least 24-48 hours. One of the most common causes of negative culture report is previous antibiotic treatment. The 24-48 hour period is to wash off the effect of antibiotics. Once the wash off period is over, steps similar to that in a fresh case of corneal ulcer are repeated. An adequate corneal scraping sample is taken as described above and immediately sent for microbiological investigations. The smears and stains should be done immediately without delay to increase the probability of growth. Also the plating on the culture plates should be direct. Once the scraping is done, the empirical treatment based on history or examination may be started. This treatment may be altered according to the smear or culture report once that is obtained.

In case of a negative culture after repeat scraping as well, other methods of sample collection such as corneal biopsy or suture biopsy may be tried especially for deeper non responding ulcers. Confocal microscopy also has a role in such cases.

Empirical therapy for a case of corneal ulcer usually includes broad spectrum antibiotics such as fortified cefazolin 5 percent and fortified tobramycin 1.3 percent along with a cycloplegic for cyclitic pain relief. Large ulcers with impending perforation or with sclera involvement or posterior segment involvement in the form of endophthalmitis may require systemic antibiotics as well.

Once the causative micro organism is identified after the microbiological investigations, the treatment is accordingly altered.

### ● Bacterial keratitis

For small peripheral bacterial corneal ulcers, monotherapy with a topical fluoroquinolone may be sufficient. With the advent of fluoroquinolone resistant micro organisms especially Moxifloxacin resistant Staphylococcus aureus, topical vancomycin 5 percent has found favour in such patients. For larger ulcers, fortified therapy may be needed according to culture sensitivity. Most bacteria are sensitive to the empiric therapy of cefazolin-tobramycin itself and it usually continues then. The therapy in the initial period is intensive with hourly application.

### ● **Fungal keratitis**

For suspected filamentous fungal infections, 5 percent natamycin is the initial treatment of choice. Topical voriconazole 1 percent may be used in adjunct to topical natamycin for filamentary fungal keratitis and has been shown to be effective in the MUTT trial<sup>19</sup>. Topical 0.15 percent amphotericin B may be used in case of suspected yeast infection. Oral antifungals may be given in case of large ulcers with sclera involvement or associated endophthalmitis or with impending perforation.

### ● **Acanthamoeba keratitis**

Cysticidal therapy includes biguanides such as PHMB 0.02% and propamidine 0.1% or brolene. Other agents include chlorhexidine 0.02% may be used in place of PHMB. Topical steroids may be added in case of progressive vascularisation in such cases.

### ● **Viral keratitis**

The treatment in case of a viral keratitis depends on the type of keratitis. In case of a purely epithelial dendritic keratitis, antivirals alone are the treatment of choice and steroids should be avoided. A topical steroid in adjunction with oral antivirals is the treatment of choice for stromal keratitis and endothelitis. The balance between topical steroids and antivirals is needed in case of stromal or endothelial keratitis along with epithelial involvement.

Non resolving corneal ulcer which fails to respond to the above standard protocols is a therapeutic challenge and an ophthalmologist's dilemma. Several newer treatment regimens have been tried especially for non responding corneal ulcers.

### ● **Collagen cross linking in case of recalcitrant corneal ulcer**

Several studies have evaluated the role of collagen cross linking in a case of non healing corneal ulcer. Some of these studies were in vitro and showed the beneficial bactericidal effect of 365 nm UVA photo activated riboflavin. Tsugita et al showed that UVA-riboflavin combination deactivates RNA in tobacco mosaic virus<sup>20</sup>. Collagen crosslinking using 365 nm UVA and riboflavin solution has been shown to have a role in preventing corneal melt caused by Gram-negative bacteria (92%) followed by Gram-positive bacteria (84%), acanthamoeba (71%) and fungi (61%)<sup>21-27</sup>. Shetty R et al reported that CXL is an effective procedure in treating non-resolving microbial keratitis with superficial stromal involvement<sup>28</sup>. They further

revealed that the prognosis was better in case of bacterial keratitis as compared to fungal keratitis which was deeper. Hence CXL may be used as an adjunct to the standard therapy. CXL in these cases also gives early symptomatic relief to the patients by decreasing corneal sensations and hence reducing the pain.

### ● **Role of intrastromal voriconazole injection in recalcitrant fungal corneal ulcer**

Targeted drug delivery using intrastromal injection of the anti fungal agent especially voriconazole has been shown

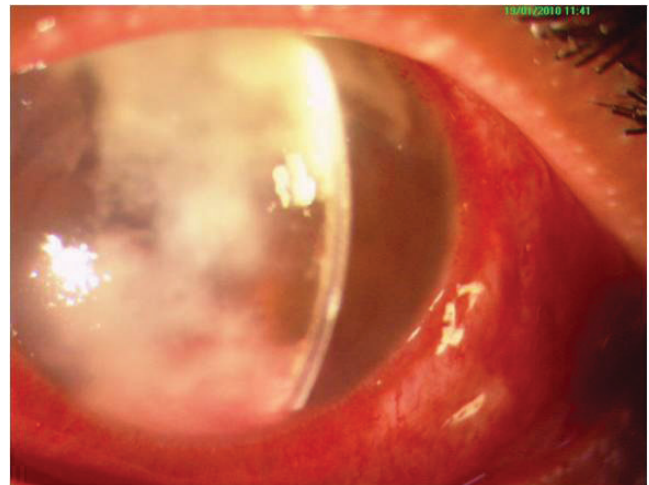


Figure 2a. Clinical photograph in a case of non resolving fungal keratitis (baseline)

to be effective in cases of fungal keratitis. Intrastromal voriconazole in the dose of 50 µg/0.1 ml is administered using 1 ml tuberculin syringe and 26 gauge needle. It is inserted obliquely into the cornea from uninvolved area

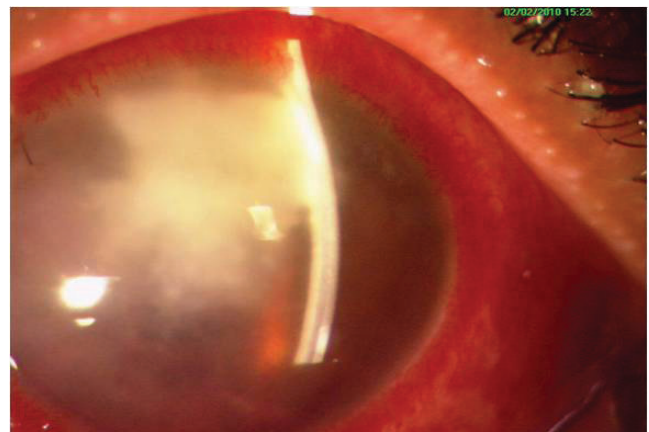


Figure 2b. Clinical photograph demonstrating the effect of topical natamycin 5% along with 1% intrastromal Voriconazole in a case of non resolving fungal keratitis at week 1

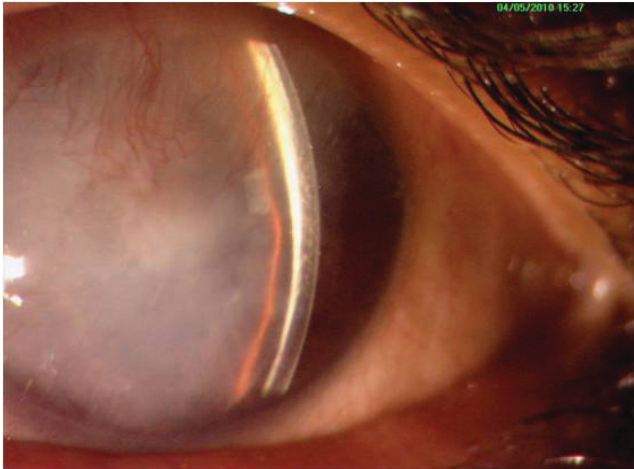


Figure 2c. Clinical photograph demonstrating the effect of topical natamycin 5% along with 1% intrastromal Voriconazole in a case of non resolving fungal keratitis at week 4

and a barrage is made all around the involved or ulcerated area. These injections may be repeated 72 hours later. In a study published in 2011, Sharma N et al injected intrastromal voriconazole in 12 eyes with recalcitrant fungal keratitis<sup>29</sup>. Of these, 10 eyes healed with scar formation (Figure 2 a,b,c) while two eyes required therapeutic penetrating keratoplasty. In another study by Sharma N et al, forty cases of fungal corneal ulcer not responding to standard topical natamycin 5 percent drops for 2 weeks were randomised into treatment with either hourly topical voriconazole or at least three intrastromal voriconazole injections<sup>30</sup>. There was no statistical difference in mean duration to healing. The incidence of perforation and posterior synechiae were similar while pain was significantly more frequent in the intrastromal group.

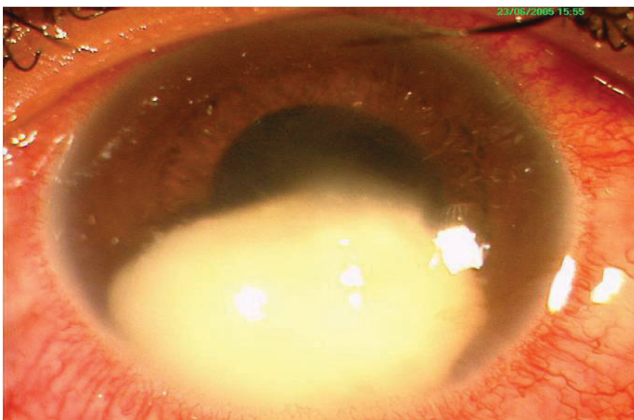


Figure 3a. Pre operative clinical photograph of fungal keratitis with fungal ball in the anterior chamber

### ● *Role of Intracameral and Intrastromal voriconazole in recalcitrant fungal keratitis with hypopyon*

Previous studies have shown that the experimental use of intracameral voriconazole in humans shows no toxic effects when the aqueous concentration is in the safe range of 10µg/mL - 1.5mg/mL. There may be a reduction in corneal endothelial cells, trabecular meshwork cells, and retinal pigment epithelial cells in dose more than 1.5mg/ml<sup>31</sup>. In the safe range, intracameral voriconazole can be used in adjunct with intrastromal voriconazole in recalcitrant cases with hypopyon. (Figure 3a and 3b)

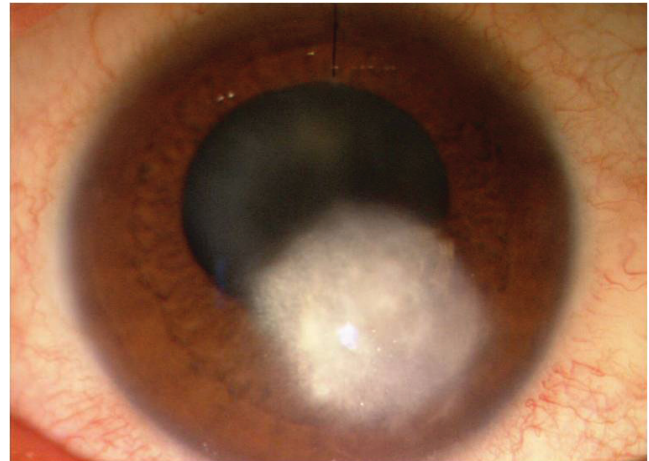


Figure 3b. Post operative day 14 clinical photograph of intracameral along with intrastromal voriconazole

### ● *Other novel methods of antifungal drug delivery in deeper recalcitrant ulcers*

Pallikaris et al in 2015 published a report where they successfully used Femtosecond laser to create a corneal pocket for direct instillation of antifungal drug deeper into the cornea<sup>32</sup>.

Natamatrix, a tiny dissolvable matrix which can be inserted into stroma is another novel technique being described for targeted drug delivery.

### ● *Role of therapeutic penetrating keratoplasty (TPK)*

Several studies have shown that Therapeutic PK has a role in the management of severe and refractory keratitis with a high success in restoring anatomical integrity. But on the other hand graft re infection rates are high especially in case of fungal and acanthamoeba keratitis<sup>33</sup>.



## Conclusion:

Recalcitrant microbial keratitis is a challenge to every ophthalmologist. Its management involves a step by step approach. Timely diagnosis and intervention may save the ulcer from perforation. Newer modalities such as Collagen cross linking, intrastromal and intracameral drug injections and other methods of targeted drug delivery may be tried.

## References:

- Whitcher JP, Srinivasan M, Upadhyay MP. Corneal blindness: a global perspective. *Bull World Health Organ* 2001; 79: 214–21.
- Burd EM, Ogawa GSH, Hyndiuk RA. Bacterial keratitis and conjunctivitis. In: Smolin G, Thoft RA, eds. *The cornea scientific foundations and clinical practice*. 3rd edn. Boston: Little, Brown, & Co, 1994:115–67.
- Gokhale NS. Medical management approach to infectious keratitis. *Indian J Ophthalmol*. 2008; 56: 215-20.
- Bertino J S. Impact of antibiotic resistance in the management of ocular infections: the role of current and future antibiotics. *Clin Ophthalmol* 2009; 3: 507–21.
- Keay L, Edwards K, Naduvilath T, et al. Microbial keratitis predisposing factors and morbidity. *Ophthalmology* 2006; 113: 109–16.
- Maheshwari R, Weis E. Thyroid associated orbitopathy. *Ind J Ophthalmol* 2012; 6: 87-93.
- Aristimuño B, Nirankari VS, Hemady RK, Rodrigues MM. Spontaneous ulcerative keratitis in immunocompromised patients. *Am J Ophthalmol*. 1993; 115: 202–8.
- Yildiz Eh et al. Trends in contact lens-related corneal ulcers at a tertiary referral center. *Cornea* 2012 Oct; 31: 1097-102.
- D. Yorston, A. Foster. Traditional eye medicines and corneal ulceration in Tanzania. *J Trop Med Hyg* 1994; 97: 211–4.
- Guidera AC, Luchs JI, Udell IJ. Keratitis, ulceration and perforation associated with topical nonsteroidal anti-inflammatory drugs. *Ophthalmology* 2001;108: 936-44.
- Solomon A, Karp CL, Miller D, Dubovy SR, Huang AJ, Culbertson WW. Mycobacterium interface keratitis after laser in situ keratomileus. *Ophthalmology* 2001; 108: 2201–8.
- Vajpayee RB, Angra SK, Sandramouli S, Honavar SG, Chhabra VK. Laboratory diagnosis of keratomycosis: comparative evaluation of direct microscopy and culture results. *Ann Ophthalmol* 1993; 25: 68–71.
- Bharathi MJ, Ramakrishnan R, Meenakshi R, Mittal S, Shivakumar C, Srinivasan M. Microbiological diagnosis of infective keratitis: comparative evaluation of direct microscopy and culture results. *Br J Ophthalmol* 2006; 90: 1271-6.
- Gopinathan U, Sharma S, Garg P, Rao GN. Review of epidemiological features, microbiological diagnosis and treatment outcome of microbial keratitis: Experience of over a decade. *IndiJ Ophthalmol* 2009;57:273-9.
- Liesegang TJ, Forster RK. Spectrum of microbial keratitis in South Florida. *Am J Ophthalmol* 1980; 90: 38–47.
- Alexandrakis G, Haimovici R, Miller D, et al. Corneal biopsy in the management of progressive microbial keratitis. *Am J Ophthalmol* 2000;129: 571–6.
- Sridhar MS, Sharma S, Gopinathan U, Rao GN. Anterior chamber tap: diagnostic and therapeutic indications in the management of ocular infections. *Cornea* 2002; 21: 718–22.
- Presterl E, Mueller-Urri P, Grisold A, Georgopoulos A, Graninger W. Ciprofloxacin- and methicillin-resistant staphylococcus aureus susceptible to moxifloxacin, levofloxacin, teicoplanin, vancomycin and linezolid. *Eur J Clin Microbiol Infect Dis* 2001; 20: 486–9.
- Prajna NV, Krishnan T, Mascarenhas J, et al. The Mycotic Ulcer Treatment Trial: A Randomized Trial Comparing Natamycin vs Voriconazole. *JAMA ophthalmol* 2013;131:422-9.
- Tsugita A, Okada Y, Uchara K. Photosensitized inactivation of ribonucleic acids in the presence of riboflavin. *Biochim Biophys Acta* 1965;103:360–3.
- Price MO, Tenkman LR, Schrier A, Fairchild KM, Trokel SL, Price FW Jr. Photoactivated riboflavin treatment of infectious keratitis using collagen cross-linking technology. *J Refract Surg* 2012; 28: 706–13.
- EI-Danasoury AM, Hashem AN. Corneal collagen crosslinking in the treatment of infectious keratitis. *Clin Ophthalmol* 2011; 5: 1277–80.
- Morén H, Malmjö M, Mortensen J, et al. Riboflavin and ultraviolet a collagen crosslinking of the cornea for the treatment of keratitis. *Cornea* 2010; 29: 102–4.
- Iseli HP, Thiel MA, Hafezi F, et al. Ultraviolet A/riboflavin corneal cross-linking for infectious keratitis associated with corneal melts. *Cornea* 2008; 27: 590–4.
- Makdoui K, Mortensen J, Crafoord S. Infectious keratitis treated with corneal crosslinking. *Cornea* 2010; 29: 1353–8.
- Khan YA, Kashiwabuchi RT, Martins SA, et al. Riboflavin and ultraviolet light a therapy as an adjuvant treatment for medically refractive Acanthamoeba

- keratitis: report of 3 cases. *Ophthalmology* 2011;118: 324–31.
27. Martins SA, Combs JC, Noguera G, et al. Antimicrobial efficacy of riboflavin/UVA combination (365 nm) in vitro for bacterial and fungal isolates: a potential new treatment for infectious keratitis. *Invest Ophthalmol Vis Sci* 2008; 49: 3402–8.
  28. Shetty R, Nagaraja H, Jayadev C, Shivanna Y, Kugar T. Collagen crosslinking in the management of advanced non-resolving microbial keratitis. *Br J Ophthalmol* 2014; 98:1033-5.
  29. Sharma N, Agarwal P, Sinha R, Titiyal JS, Velpandian T, Vajpayee RB. Evaluation of intrastromal voriconazole injection in recalcitrant deep fungal keratitis: case series. *Br J Ophthalmol* 2011; 95: 1735–7.
  30. Sharma N<sup>1</sup>, Chacko J, Velpandian T, et al. Comparative Evaluation of Topical versus Intrastromal Voriconazole as an Adjunct to Natamycin in Recalcitrant Fungal Keratitis. *Ophthalmology* 2013; 120: 677– 81.
  31. Haddad RS, El-Mollayess GM. Combination of Intracameral and Intrastromal Voriconazole in the Treatment of Recalcitrant Acremonium Fungal Keratitis. *Middle East Afr J Ophthalmol* 2012;19:265-8.
  32. Pallikaris IG, Kymionis GD, Plaka AD, Binder PS, Kontadakis GA, Tsoulnaras KI. Femtosecond laser-assisted Intra-corneal drug delivery. *Semin ophthalmol* 2015;30:457-61.
  33. Sharma N, Jain M, Sehra SV, Maharana P, Agarwal T, Satpathy G, Vajpayee RB. Outcomes of therapeutic penetrating keratoplasty from a tertiary eye care centre in northern India. *Cornea* 2014; 33: 114–8.

Cite this article as:

Rathi A, Sharma N, Aron N, Sinha R, Agarwal T. Recalcitrant corneal ulcer. *Current Indian Eye Research* 2016; 3:45-54.